

# Role of Modified B-lynch Suture in Modern Day Management of Atonic Postpartum Haemorrhage

Vaman B Ghodake\*, Suchitra N Pandit\*\*, Shashikant M Umbardand\*\*\*

## Abstract

**Aims and Objectives :** To evaluate effectiveness of modified B-Lynch suture in controlling atonic PPH.

**Study and Observations :** A prospective study conducted at LTMG Hospital and LTMM College, Sion, Mumbai, a tertiary referral centre. We evaluated 73 cases of atonic PPH over a period of two and half years from May 2004 to Oct. 2006. In 31 patients out of 73 we used modified B-Lynch suture. Out of these 31 patients five had postoperative pyrexia and three patients had superficial wound gap. There were no major surgical complications.

**Conclusion :** Modified B-Lynch suture was successful in controlling PPH and averting obstetric hysterectomy.

## Introduction

Postpartum Haemorrhage (PPH) remains a significant contributor to maternal morbidity and mortality both in developing countries<sup>1,2</sup> and in Hospitals well equipped with all that modern medicine. ATONIC uterus is one of the preventable causes of postpartum haemorrhage. It constitutes 80% of cases of postpartum haemorrhage.<sup>3</sup>

However few patients will require surgical intervention. Traditionally the various modalities included uterus packing, stepwise devascularisation of uterus, internal iliac artery ligation and if these fail, obstetric hysterectomy, B-lynch suture and its modifications have added a new modality in the hands of the treating obstetricians before proceeding to obstetric hysterectomy.<sup>4</sup>

**Incidence** – PPH complicates approximately 3.9% of vaginal and 6.4% of

caesarean deliveries.<sup>5</sup> PPH has serious consequences and accounts for approximately 35% of maternal deaths in USA.<sup>6</sup> In India 25.6% of maternal deaths are due to haemorrhage.<sup>7</sup>

## Stepwise Approach to the Management of Postpartum Haemorrhage

### Initial assessment and treatment

The patient's general condition and amount of blood loss should be quickly assessed. Immediate attempt to find the cause of haemorrhage by a thorough exploration of uterus and inspection of lower genital tract should be performed along with instituting resuscitative measures. Absence of genital tract lacerations and presence of flabby uterus is suggestive of ATONIC PPH.

### Management of atonic uterus

#### Medical management

Several drugs are available to treat uterine atony. They should be employed in a methodical fashion, while maintaining uterine massage and compression. The

\*A/P, Birnal, Tal. - Jat, Dist. - Sangali. P.B. No. 416 404; \*\*6-Little Star, Ram Krishna Mission Marg, Santacruz (W), Mumbai - 54; \*\*\*1550/51, Behind Post Office, Subhash Nagar, Barshi 413 401, Dist. - Solapur.

current available products include oxytocin, methylergometrine and prostaglandins.

### **Uterine massage and manual compression**

The uterus is firmly squeezed between the two hands. It may be necessary to continue the compression for a prolonged period until the tone of the uterus is regained. This is evidenced by absence of bleeding, if the compression is released.

### **Uterine packing**

A 5 meters long strip of gauze, 8 cm wide folded twice as required. The gauze should be soaked in antiseptic cream before insertion. The gauze is placed high up and packed in the fundal area while the external hand steadies the uterus. Usually several roller gauze are needed, which can be joined together by knotting. Specially designed gauze tampons are available for the purpose.<sup>8</sup>

When the adequate pressure in the uterus can not be achieved using a gauze pack, it may be possible to staunch the bleeding by inflating an appropriately designed balloon inside the uterus. If a specially designed balloon is not available, the gastric balloon of Sengstaken-Blakemore tube (designed to arrest bleeding from oesophageal varices), can be used successfully.<sup>9</sup>

### **Uterine compression sutures (Brace sutures, B-Lynch sutures)<sup>4</sup> :**

In 1997, B-Lynch *et al*<sup>4</sup> described the use of uterine compression sutures to uterine atony in five cases of massive obstetric haemorrhage. The objective of this technique is to compress the uterus without occluding either the uterine arteries or the uterine cavity. Several subsequent publications reporting six more cases have attested to its efficacy. Key points in the technique are :-

- The abdomen is opened via a Pfannenstiel

incision (although a Modified Joel Cohen's procedure would be just as appropriate).

- Bimanual compression is applied to check that this arrests bleeding, before the suturing is performed.
- A lower-segment incision in the uterus is made or re-opened to allow the suturing to be performed.
- The uterine cavity is not crossed
- Vicryl or Dexon sutures are used
- The suture must be pulled tight to achieve appropriate apposition (Figs. 1 and 2).
- Richard Hayman and Professor Subaratnam Arulkumaran in Derby modify this procedure of B-Lynch suture independently. In this modified approach, there is no need to open the uterine cavity. No. 2 Vicryl or Dexon on long

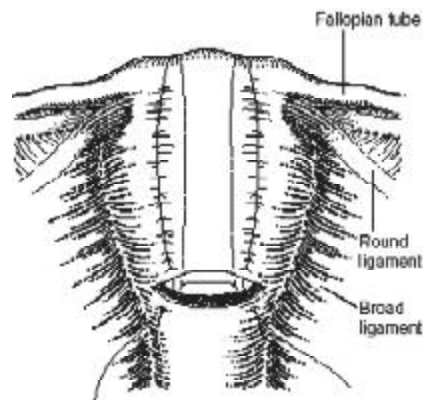


Fig. 1 : Insertion of B- Lynch Suture

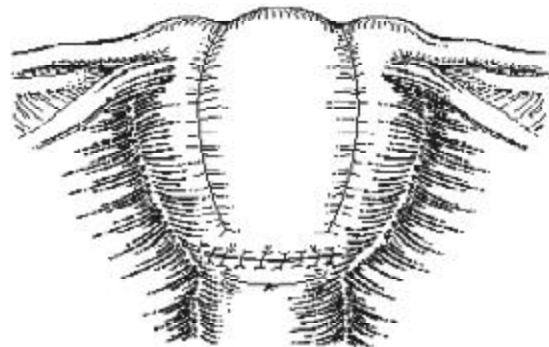


Fig. 2 : B-Lynch suture tied

straight needle is used to transfix the uterus from front to back, just above the reflection of the bladder and is then tied at the fundus of the uterus.

This can be done as one suture on each side of the uterus, or more than one suture if the uterus is particularly broad, and more than one suture appears to be necessary to obtain adequate compression (Fig. 3).

If only two sutures are needed, there is sometimes a tendency for the suture to slide off the uterus, like the braces off a round-shouldered man. To prevent this, the simplest technique is to tie the knots at the top of uterus and then tie the loose ends together. If the uterus in between the two lateral sutures still appears to be in need of further compression, then side-to-side ties can be inserted in between the lateral sutures (Figs. 4 and 5).

#### Vascular catheters and embolization<sup>10</sup>

The technique of arterial embolization to arrest major postpartum haemorrhage was reported as long ago as 1979<sup>10</sup> and sporadic reports appeared during the 1980s. However, more systematic use has only been reported in the past few years. Most reports suggest it is useful in expert hands,<sup>11</sup> which occlude larger arteries such as the internal iliac. Complications from embolization are

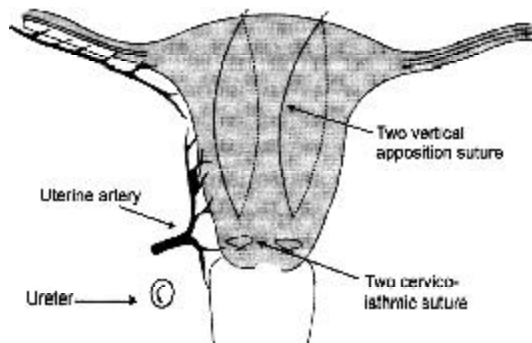


Fig. 3 :Modification by Prof. S. Arulkumaran

uncommon, affecting about 5-10% of patients, and mainly comprise infection and fever. However, as with almost any technique, rare but fatal complications can occur, a death from septicaemia following embolization of fibroids in a non-pregnant woman has been reported.<sup>12</sup> There is a necessary exposure of the mother (and foetus, if placement of catheters is done pre-delivery) to 10-15 rad of radiation.<sup>10</sup> The use of the technique is, of course, limited by the availability of the specialized imaging equipment required (including) a radiology table), and the relative shortage of suitably trained interventional radiologists, who must also be on standby to arrive at short notice for emergency procedures. Even in units with appropriate

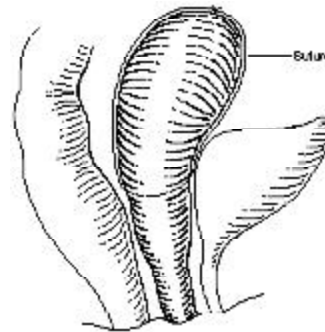


Fig. 4 :Lateral view of uterus, showing where compression suture placed

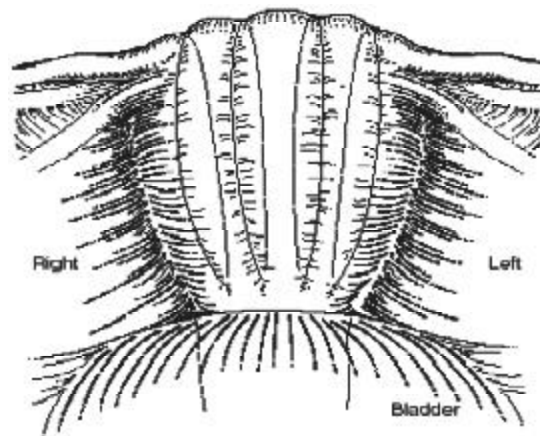


Fig. 5 :Front View of uterus, showing where compression sutures are placed

equipment and staff, it will be difficult to institute such therapy in less than 45 min (Fig. 6).

### Stepwise devascularisation<sup>13</sup>

This procedure consists of the following steps :-

- **Ligation of uterine arteries:** Ascending branch of uterine artery is ligated at the lateral border between upper and lower uterine segment. The suture (No. 1 chromic catgut) is passed into the myometrium 2 cm medial to the artery. In atonic haemorrhage bilateral ligation is effective in about 75% of cases.
- **Ligation of the ovarian and uterine artery anastomosis** if bleeding continues is done just below the ovarian ligament. Rarely temporary occlusion of the ovarian vessels at the infundibulopelvic ligament may be done by rubber sleeved clamps (Fig. 7).
- **Ligation of anterior division of internal iliac artery (unilateral or bilateral) :** It reduces the distal blood flow. It helps stable clot formation by reducing the pulse pressure up to 85%.

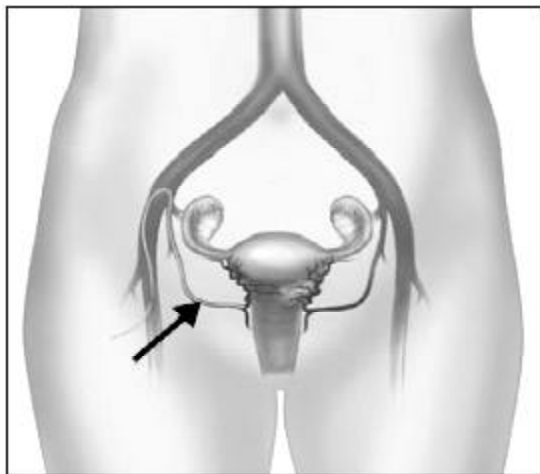


Fig. 6 :Catheter placed in the uterine artery.  
Courtesy San Jaoquin Community Hospital

Due to extensive collateral circulation, there is no pelvic tissue necrosis. Bilateral ligation (not division) can avoid hysterectomy in about 50% of the cases.

### Internal iliac ligation

In desperation, blood flow to the pelvis can be reduced by ligation of the internal iliac artery (also known as the hypogastric artery). This requires incision of the peritoneum on the lateral sidewall of the pelvis. Ligation must be done distal to the origin of the posterior branch that if ligated, can result in compromised blood flow to the gluteal muscles. The reported success of the procedure ranges from 43 to 90%.<sup>15</sup> However, the procedure is not taught to most trainees in obstetrics and gynaecology in the UK, and it is therefore necessary, in most cases, to involve a vascular surgeon or gynaecological oncologist in the operation. If bleeding has not responded to uterine compression sutures and/or ligation of the uterine artery, then the obstetric surgeon will have to consider carefully whether any further delay in performing a hysterectomy is appropriate (Fig. 8).

### Caesarean hysterectomy

Hysterectomy can be a life saving procedure, and it should be considered as soon as it is apparent that haemorrhage may pose a threat to the woman's life, and/or the

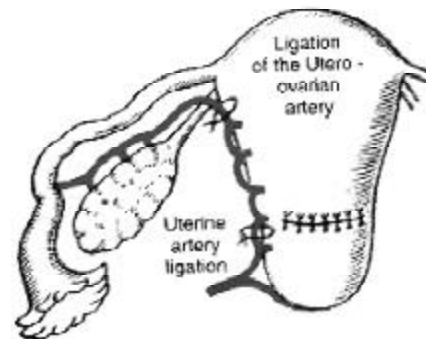


Fig. 7 :Ligation of utro-ovarian artery

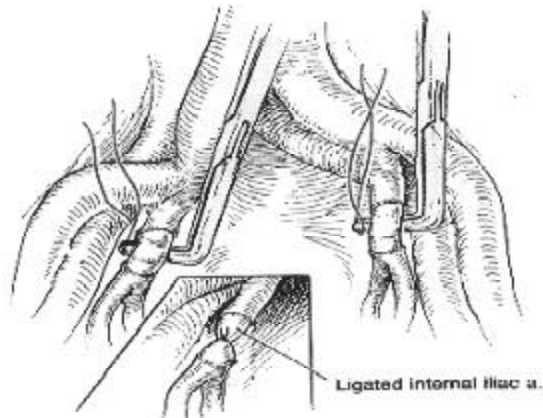


Fig. 8 : Internal Iliac Artery Ligation

conservative measures described above are not available or are not working.

The classical indications are (in order of frequency) :-

- uterine atony (43%)
- placenta accreta (30%)
- uterine rupture (13%)
- extension of a low transverse incision (10%)
- leiomyomata preventing uterine closure and haemostasis (4%).<sup>14</sup>

### Objective

To evaluate the role of modified B-Lynch suture in modern day management of atonic postpartum haemorrhage

### Study and Observations

A prospective ongoing study conducted at L.T.M.G. Hospital and L.T.M. Medical College, Sion; Mumbai, a 1423 bedded tertiary municipal hospital evaluated 73 cases of atonic postpartum haemorrhage over a period of two and half years from May 2004 to October 2006. Most of these cases were referred to this institute on an emergency basis.

Table 1 shows different surgical modalities used for management of atonic PPH after failure of medical management. Two patients

Table 1 : Types of surgical management

Surgical management	Number of cases
Uterine packing	02
Uterine artery ligation + IIA ligation	04
Modified B-Lynch suture	31
Obstetric hysterectomy	36

Table 2 : Comparison of postoperative complications between B-Lynch suture and obstetric hysterectomy

Complications	B-lyncb suture	Obstetric Hysterectomy
Major –		
Vasico-vaginal fistula	—	2
Deep venous thrombosis	—	1
Maternal mortality	—	2
Minor –		
Fever	05	10
Wound gape	03	06




Fig. 9 : Type of surgical management

underwent uterine packing and four stepwise devascularisation in the form of uterine artery ligation + IIA ligation. 36 patients required obstetric hysterectomy while in 31 cases modified B-Lynch suture was used (Fig. 9).

Table 2 shows that there are no major postoperative complications with B-Lynch suture as compared to obstetric hysterectomy.

### Discussion

Uterine packing was successful in two

cases and uterine artery ligation with Internal Iliac Artery (IIA) ligation was done in four cases. Modified B lynch suture was used in 31 patients. One patient of these required obstetric hysterectomy for control of PPH and another one patient required stepwise devascularisation in the form of uterine artery ligation and IIA ligation.

Previously before introduction of B-Lynch suture obstetric hysterectomy was performed for atonic PPH, if stepwise devascularisation of uterus failed.

This shows that modified B-Lynch suture should be tried in all cases of atonic PPH before proceeding to stepwise devascularisation of uterus and obstetric hysterectomy.

The advantages of B lynch suture can be summarized as follows :-

- Cost effectiveness
- Easy to perform

### **Surgical Complications**

In the present study 31 patients underwent modified B-Lynch suture out of which five patients had postoperative pyrexia and three patients had superficial wound gap. There were no major surgical complications. However the group of patients which required obstetric hysterectomy (36 patients) had major surgical complications like vesico-vaginal fistula (two cases) deep venous thrombosis (one case) and two maternal mortalities due to severe hypo-volaemic shock.

### **Why B lynch brace suture should be modified?**

1. On review of literature, only 1200 cases of B-Lynch suture were reported.
2. In few cases of these partial necrosis and sloughing of uterine wall was noted.<sup>15</sup>
3. Some authors also reported erosion of

uterine wall.<sup>16</sup> Compression of an already ischaemic uterus due to excessive bleeding and prolonged labour may further aggravate necrosis and infection varying from 15-50%.

4. to treat cases in absence of LSCS incision.

### **B-Lynch Brace suture Vs Modified B-Lynch Brace suture**

Comparison of B-Lynch suture with its modification is shown in Table 3.

As shown in Table 3, it can be seen that the original Crystopherson B-Lynch suture requires expertise and re-opening of uterine incision or an incision over lower uterine segment. It is time consuming and there is bleeding from uterus due to multiple bites.

However, uterine reopening is avoided with modified B-Lynch brace suture. Cervical stenosis, haematometra, partial necrosis and sloughing of uterine wall have been documented by various surgeons as a complication of the original B-Lynch brace suture.

Since the modified B lynch brace suture is a newer technique, and most of the studies are based on case reports and are without proper controlled studies, more controlled studies are required before it is accepted as a

**Table 3**

B-Lynch brace suture	Modified B-Lynch brace suture
1. Requires expertise	1. Easy to perform
2. Transverse LUS incision required	2. LUS incision not required
3. Time consuming	3. Less time consuming (can be completed in 2-3 min)
4. Cervical stenosis	4. No cervical stenosis
5. Haematometra formation	5. No haematometra formation
6. Bleeding from LUS due to multiple bites	6. No bleeding from LUS

standard method.

### Conclusion

- Modified B-Lynch brace suture was successful in controlling PPH and averting obstetric hysterectomy (OH) in 93.56% of cases
- 3.22% (One patient) required obstetric hysterectomy after B-Lynch suture
- 3.22% (one patient) required selective devascularisation of uterus in addition to B-Lynch suture

### References

1. Kwast BE. Postpartum haemorrhage: its contribution to maternal mortality. *Midwifery* 1991; 7 : 64-70.
2. World Health Organisation. Maternal Mortality : A Global Factbook. Geneva, WHO 1991b.
3. Obstetric Haemorrhage Williams Obstetrics 22<sup>nd</sup> edition, McGraw-Hill Medical Publication division, 2005 : 823-24.
4. B-lynch C, Coker A, Lawal AH, *et al.* The B-lynch surgical technique for the control of massive postpartum haemorrhage: an alternative to hysterectomy? Five cases reported. *British Journal of Obstetrics & Gynaecology* 1997; 104 : 372-5.
5. Combs CA, Murphy EI, Laros RK. Factors associated with postpartum haemorrhage with vaginal birth. *Obstet Gynecol* 1991;77 : 69-76.
6. Combs CA, Murphy EI, Laros RK. Factors associated with postpartum haemorrhage with vaginal birth. *Obstet Gynecol* 1991; 77 : 77-82.
7. Kaunitz AM, Hughes JM, Grimes DA, *et al.* causes of maternal mortality in United States. *Obstet Gynecol* 1985; 65 : 605-82.
8. Registrar general of India in health information India, Ministry of health, New Delhi, 1998. disorder of amniotic fluid volume chapter 21. Williams Obstet. 22 Edition Megram - Hill Medical publishing division P 525-34.
9. Robie GF, Morgan MA, Payne GGJ, Wasemiller-Smirh L. Logothetopoulos pack for the management of uncontrollable postpartum haemorrhage. *American Journal of Perinatology* 1990; 7 : 327-28.
10. Johanson R, Kumar M, Obhrai M, Young P. Management of massive postpartum haemorrhage : use of hydrostatic balloon catheter to avoid laparotomy. *British Journal of Obstetrics and Gynaecology* 2001; 108 : 420-2.
11. Brown BJ, Heaston DK, Poulson AM, *et al.* Uncontrollable postpartum bleeding: a new approach to hemostasis through angiographic arterial embolization. *Obstetrics & Gynaecology* 1979; 54 : 361-5.
12. Oei PL, Chua S, Tan L, *et al.* Arterial embolization for bleeding hysterectomy for intractable postpartum hemorrhage. *International Journal of Gynecology and Obstetrics* 1998; 62 : 83-6.
13. Vashisht A, Stud J, Carey A Burn P. Fatal septicemia after fibroid embolisation. *Lancet* 1999; 354 : 307-8.
14. Clark SL, Yeh SY, Phelan JP, *et al.* Emergency hysterectomy for obstetric haemorrhage. *Obstetrics and Gynecology* 1984; 64 : 376-80.
15. Review of B-Lynch brace suture, *Br Journal of Obstetrics and Gynaecology* 2004; 111 (3) : 279-80.
16. B-Lynch brace suture, a technique for atonic postpartum haemorrhage. *J Reproductive Med* 2004; 49 (10) : 849-52.