

The Different Facets of Haemolympathic Malignancies – An Autopsy Study of 10 Cases

Vinaya B Shah*, Madhavi S Deokar**, Charu J Modi*, Shilpa Lad***, Asha B Rupani***, B Meenakshi*

Abstract

Background : Although hemolympathic malignancies are known to present with fever of unknown origin (FUO), widespread disease with predominance of involvement of a particular organ or system can mislead clinical identification. We reviewed 10 cases of undiagnosed haemolympathic malignancies with a widespread dissemination as a terminal event at autopsy.

Results : Total hospital stay ranged from 20 minutes to 24 hours and all the cases had history of fever of unknown origin. Other presenting features were acute hepatitis (3 cases), bleeding tendencies (2 cases). Majority of patients received symptomatic antipyretic treatment, Anti Koch's treatment (2 cases) and antiviral treatment (3 cases). On autopsy, out of the 10 cases, 6 cases were of acute leukaemia and 4 of lymphoma

Conclusion : Widespread dissemination of leukaemia and lymphoma often present with wide range of symptoms such that they are misdiagnosed as infectious diseases. Hence there should be a greater awareness of such protean manifestations in a case of haemolympathic malignancies for early diagnosis.

Introduction

It is a well known fact that haemolympathic malignancies can have varied presentations which can mimic infective diseases like malaria, leptospirosis, dengue especially if associated with the symptom of fever of unknown origin (FUO) and systemic illness like jaundice, hepatitis, coagulation disorder.

Disseminated malignancies involve multiple organs posing difficulty in diagnoses. Extranodal involvement by the lymphomatous process may be missed. We came across 10 cases out of 940 autopsies performed over a period of 2 years at postmortem in a tertiary care hospital. We

pursued to study these cases and highlight the clinical presentations of disseminated haemolympathic malignancies which were missed antemortem.

Material and Methods

This was a study of 10 cases retrieved from autopsy material over 2 year period (Year 2006 and 2007) from total 940 autopsies. The cases selected were disseminated haemolympathic malignancies diagnosed after post mortem histopathological examination which were not suspected clinically in the antemortem period. The patients who were dead after the clinical diagnosis of leukaemia or lymphoma were excluded from the study.

Results

Table 1 gives brief history on these 10 cases with clinical features, antemortem

*Associate Professor; **Resident; ***Lecturer; Dept. of Pathology, TN Medical College and BYL Nair Ch. Hospital, Mumbai - 400 008.

Table 1 : Summary of 10 case

Sr. No. and Age / Sex	Clinical features	Antemortem Investigations	Clinical impression	Post Mortem Diagnosis
Case 1 17/M	Fever thrombocytopenia	Hb- 7.6 gm % Plt-15000/cumm Lepto - negative	-Leptospirosis -Dengue	Acute Leukaemia
Case 2 35/F	Fever Thrombocytopenia	Hb- 5.1 gm % Lepto/dengue - negative	-Leptospirosis -Dengue	Acute Leukaemia
Case 3 33/M	Fever Jaundice	No investigations Total hospital Stay- 50 min.	f/o Acute hepatitis	Acute Leukaemia
Case 4 55/M PM192/05	Fever with Chills, Massive splenomegaly	PS MP- Neg Hb- 11 gm % Total hospital Stay- 30 min	Malaria	Acute Leukaemia
Case 5 33/M	Fever Jaundice Hepato- splenomegaly	Hb- 5.6 gm% TC- 3700/cumm T.Bil- 11 gm%	f/o Acute hepatitis	Acute leukaemia
Case 6 53/M	Fever Left forearm cellulitis	Hb- 6 gm % TC- 2500/cumm Plt- 24000/cumm USG- WNL BUN-11 mg% T.Bil- 1.4 mg%	Fever with cellulitis- Pancytopenia	Multiple myeloma with Pulmonary Aspergillosis
Case 7 35/M	Fever, HIV +ve Abdominal Kochs on AKT Terminally gasping	Short hospital Stay- 30 min No investigations	c/o Abdominal Kochs on AKT	GI Lymphoma
Case 8 17/M	Fever Abdominal Kochs on AKT	Hb-6.7 mg% TC-2000/cumm T.Bil-12.2 mg% USG ABDO- Lymph nodes enlarged	Kochs with acute hepatitis? Drug induced	Non Hodgkin's Lymphoma of GI Tract
Case 9 26/F	Fever in post-partum with altered sensorium, Hepatosplenomegaly	Hb-10 gm%, TLC-9,100 USG: H-Splenomegaly with Abdo LN adenopathy	post-partum psychosis Kala azar	NHL of GI Tract and Lymphnodes
Case 10 60/F	Fever, Hepatosplenomegaly Abdo- Lymphadenopathy with Ascites	Hb-6.1 gm%, T Bilirubin-7.3mg USG: H-Pelvic mass with Abdo LN adenopathy	Ovarian malignancy	Non Hodgkin's Lymphoma of GI Tract

investigations, clinical impression and post mortem diagnosis. There were 7 males and 3 females. Age group was variable ranging from 17 years to 65 years with majority of cases

i.e. 6 in 17-35 year age group.

All the patients uniformly presented with fever. Other symptoms noted along with fever were jaundice -3, hepatosplenomegaly -4,

abdominal pain and distension-4.

The most significant finding in our study was that these patients died within 24 hours of hospital stay and 3 patients died within 1 hour stay (case 3, 5 and 7).

Hence this restricted in getting the extensive diagnostic work up of the patient including the routine investigations like complete blood count, urine , FNAC and bone marrow biopsy. These patients had history of fever which was present more than 2 weeks as elicited from the relatives. They were referred to the hospital after going through the local treatment from their local practitioners.

The bare minimum investigations available in 7 cases, anaemia was seen in all the 7 cases.

In 2 cases (case 1 and 2) patients came with bleeding disorder- purpuras, hence blood was sent for platelet count and for leptospirosis/dengue investigations.

In 2 cases (case 3 and 5), patients presented with jaundice and fever, they were diagnosed as viral hepatitis and they died within one hour before any investigations could be done. In case no. 4, patient was diagnosed of malaria infection because of fever with chills and splenomegaly. The peripheral smear sent for malarial parasite was negative, however



Fig. 1 : Gross of spleen which is enlarged and firm in consistency .

smear showed increase in leucocytes which were large and atypical and bone marrow aspiration biopsy was advised. The case no 6 was of 53 year old male diagnosed as pancytopenia after CBC and was under further evaluation to find cause for pancytopenia. He succumbed shortly after before the complete work up could be done.

On post mortem examination, out of 10 cases, 5 were acute leukaemias, 1 case of multiple myeloma and 4 were of Non – Hodgkin's lymphoma.

All 5 cases of acute leukaemia was diagnosed on smear examination of bone marrow, they were labelled as Acute myeloid leukaemia based on morphology of of leukaemic cells, auer rods and myeloperoxidase stains. One case showed abnormal plasma cells in the marrow and diagnosed as probably multiple myeloma which presented as pancytopenia. This case showed extensive pulmonary aspergilloses.

The gross morphology of all cases showed enlarged spleen (Fig. 1), liver and kidney. Microscopy showed extensive leukaemic infiltrate in the parenchymal organs like liver (Fig. 2), spleen, kidney (interstitial leukaemic infiltrates causing expansion) and heart (Fig. 3).

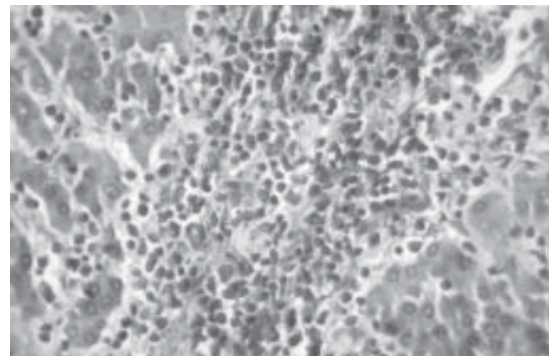


Fig. 2 : Microscopy of liver section shows extensive leukaemic infiltrate in the sinusoids and portal areas.

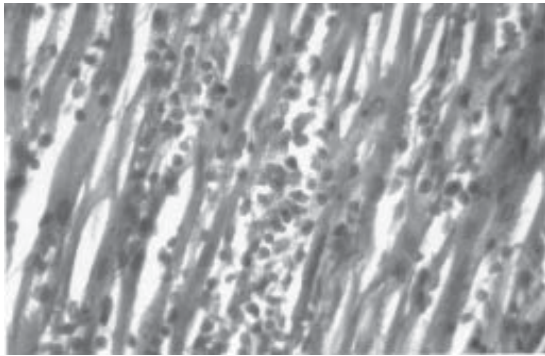


Fig. 3 : Microscopy of heart section shows leukaemic infiltrates in the myocardium.

Discussion

Fever is a common presenting problem in primary care practice. Often its cause is determined by the presence of associated localized symptoms, and its course is self-limited. Examples include upper respiratory tract infection manifesting as fever and nasal congestion and acute gastroenteritis presenting with fever and diarrhoea. Less frequently, fever occurs without localization of symptoms and is persistent. The concern with these patients is the possibility of occult disease, and diagnostic evaluation is warranted.

Febrile illnesses of less than 2 weeks' duration are often infectious in aetiology, most frequently viral, or secondary to drug toxicity, and a specific diagnosis is sometimes not established. Many systemic disorders begin with a prodrome characterized by fever, and observation ultimately leads to identification of the illness.

In 1961, Petersdorf and Beeson¹ defined fever of undetermined origin (FUO) as a febrile illness of more than 3 weeks' duration in which temperatures exceed 38.3° C (101°F) on several determinations and no diagnosis is reached after 1 week of intensive evaluation.¹ The purpose of these restrictive criteria is to eliminate most self-limited

conditions. The differential diagnosis of FUO includes infections (approximately 30% of cases), neoplastic diseases (30%), inflammatory disorders (15%), and miscellaneous conditions (15% to 20%).² Several factors may limit the applicability of research literature on FUO to everyday medical practice. These factors include the geographic location of cases, the type of institution reporting results (e.g., community hospital, university hospital, ambulatory clinic), and the specific subpopulations of patients with FUO who were studied. Despite these limiting factors, infection remains the most common cause of FUO in study reports.²⁻⁴

The presenting symptoms of acute leukaemias result from the absence of normal haematopoietic elements, along with the proliferation and accumulation of abnormal cells. The clinical findings are related to the degree of anaemia (pallor, fatigue, palpitations), thrombocytopenia (petechiae, purpura, epistaxis) and neutropenia (infections). Other signs and symptoms include hepatosplenomegaly, lymphadenopathy. Leukaemic infiltrates in parenchymal organs as liver, spleen, kidney, testes lead to firm painless enlargement of the organ.

Malignancies that sometimes are difficult to diagnose, such as chronic leukaemias, lymphomas, renal cell carcinomas, and metastatic cancers, often are found in patients with FUO.⁴ Acute febrile illness are often infectious(30%) in aetiology most frequently viral or malarial, neoplastic causes also contribute in 30%. Lymphoma and leukaemia i.e. haemolympathic malignancies are most frequent neoplastic causes of fever.

Acute leukaemia may present with high grade fever in conjunction with anaemia and leucopenias (Cases 1 and 2).

Bone marrow aspirate and biopsy are usually diagnostic. However due to short hospital stay bone marrow study was not done and clinical impression was like Leptospirosis/ Dengue, in view of thrombocytopenia.

There are many brief reports showing liver involvement with acute leukaemia giving rise to hepatitis like picture.⁵⁻⁷ In our study, 2 cases had history of jaundice with fever which suggested viral hepatitis. Associated splenomegaly with fever also made the clinicians to think as malaria in one case.

On histopathology, there was diffuse sinusoidal, portal infiltration by leukaemic cells. In many cases, haemolympathic malignancies are often present with infections. In our study, (6th case) patient had fever with diagnosed pancytopenia. Patient died with infection and complete histopathological examination revealed multiple myeloma in bone marrow and Aspergillus infection of lungs which contributed to his death.

Non-Hodgkins lymphoma is generally associated with peripheral lymphadenopathy, hepatosplenomegaly or both. Diagnosis of lymphoma is made by lymph node biopsy and bone marrow examination.

According to current concepts, most non-Hodgkin's lymphomas are thought to arise in a uni- or multifocal manner from the nodal tissue with subsequent spread to distant nodal and visceral sites. However, approximately 10-25 % of all non- Hodgkin's lymphomas appear to have an extranodal origin and have been referred to as primary extra-nodal lymphomas.⁸ In the study by Richard *et al*, where he studied series of localized primary extranodal lymphomas, out of 39 cases over a 10 year period, he had encountered 11 cases with extranodal lymphomas arising in the gastrointestinal

tract.⁸

In our study, 4 patients in case nos. 7,8,9 and 10 as mentioned in Table 1 presented with abdominal distension and pain. USG revealed abdominal lymphadenopathy and in view of fever, weight loss - possibility of abdominal koch's was considered in cases 7 and 8 and were on AKT treatment. One of the patients was HIV reactive and other patient developed jaundice due to AKT drugs. Case 9 and 10 had hepatosplenomegaly, so kala azar was considered, however in case 10, a 60 year old female also had ascites, hence probably secondary to ovarian neoplasm was thought. They both succumbed before further investigations were carried out. In autopsy, there was thickened small intestinal mucosa with enlarged, matted mesenteric lymph nodes (Fig. 4). Cut surface of lymphnodes showed fleshy white appearance with few areas of necrosis. There was no evidence of any other organ involvement. Histologically there was diffuse infiltrate by lymphomatous cells of B cell type arising from the mucosa and involving submucosa (Fig. 5).

Thus haemolympathic malignancies were not suspected in our 10 cases perhaps due to variability in clinical presentation and very short hospital stay limiting our further diagnostic work up.

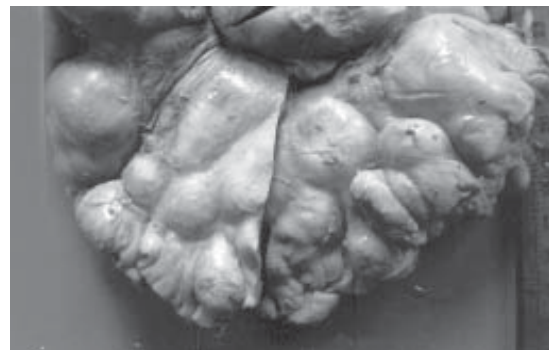

Fig. 4 : Gross appearance of the thickened small intestine with multiple enlarged mesenteric lymphnodes.

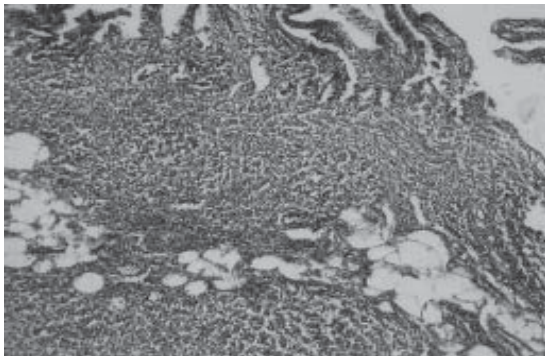


Fig. 5 : Microscopy of small intestine section shows diffuse involvement by lymphoma in the mucosa and submucosa.

Conclusion

Fever was a commonest symptom in disseminated haemolympathic malignancy. All the acute febrile illness need not to be of infective aetiology like malaria, leptospirosis. Jaundice may be the presenting feature of leukaemia or lymphoma. Anaemia especially in males with moderate to severe grade to be regarded with greater caution and investigated thoroughly. In presence of altered coagulation profile-thrombocytopenia, apart from leptospirosis and dengue, haemolympathic malignancy should be considered as one of the differential diagnosis.

Haemolympathic malignancy and tuberculosis is a known association. Lymph nodes picked on in imaging technology may be either of the two, so extra efforts should be made for confirmation.

Widespread dissemination of leukaemia or lymphoma often present with wide range of symptoms associated with fever such that they are misdiagnosed as infectious disease. Hence there should be a greater awareness of such protean manifestation in a case of haemolympathic malignancies for early diagnosis.

References

1. Petersdorf RG, Beeson PB. Fever of unexplained origin: report on 100 cases. *Medicine* 1961; 40 (1).
2. Hirschmann JV. Fever of unknown origin in adults. *Clin Infect Dis* 1997; 24 : 291.
3. De Kleijn EM, Vandenbroucke JP, van der Meer JW. Fever of unknown origin (FUO). A prospective multicenter study of 167 patients with FUO, using fixed epidemiologic entry criteria The Netherlands FUO Study Group. *Medicine [Baltimore]* 1997; 76 : 392-400.
4. Knockaert DC, Vanneste LJ, Bobbaers HJ. Recurrent or episodic fever of unknown origin. Review of 45 cases and survey of the literature. *Medicine [Baltimore]* 1993;72:184-96.
5. Rajesh G, Sadasivan S, Hiran KR, *et al.* Acute myeloid leukemia presenting as obstructive jaundice. *Indian J of Gastroenterology* 2006 ; 25 March- April 1993.
6. Mathews E, Timothy Laurie, Kenneth O'Riorden. Liver involvement with Acute Myeloid Leukemia. *Case Rep Gastroenterology* 2008; 2 : 121-4.
7. Litten JB, Rodríguez MM, Maniaci V. Acute lymphoblastic leukemia presenting in fulminant hepatic failure. *Pediatric Blood Cancer* 2006; 47 : 842-5.
8. Rudders RA, Ross ME, DeLellis RA. Primary Extra nodal Lymphoma: *Cancer* 1978; 42 : 406-16.