

Giant Tubulo-villous Adenoma of Rectum Presenting as Rectal Prolapse

Anil C Pinto*, Lawrence A Desa*, Rashmi R Pyasi**, Flavia H D'Souza***

Abstract

Most of the cases of rectal prolapse due to rectal adenoma have been reported in older people. We report a case of 32 yr old pt who was admitted with h/o rectal prolapse. She also had h/o cystosarcoma phylloides of right breast operated twice.

Introduction

Approx. 95% of all colorectal cancers arise from adenoma, a finding that underscores the importance of treatment and surveillance of gastrointestinal adenoma.

Case Report

A 32 yr old female presented in emergency with rectal prolapse of 6 hrs duration with a visible sessile mass measuring 9 x 4 cms. She had h/o spontaneous rectal bleeding since 2 weeks and tenesmus since 3 months.

Past h/o operation for cystosarcoma phylloides done 2 yr ago, with a recurrence 5 month ago.

H/o painful defaecation 5 months ago for which Racemiers procedure was done. The rectal mass was probably missed or was impalpable at that time.

Pt. was pale with Hb of 6, tachycardia and B.P. of 90/60 mmHg, abdomen was soft, no palpable lump. She was immediately taken to OT and the prolapsed rectum was repositioned back and a biopsy was taken. No further intervention could be performed at that time, as she was not fit medically. She was given blood transfusion and a decision for a definitive surgery was made after further investigations.

Histopathology – Tubulovillous adenoma of rectum

Sigmoidoscopy showed villous adenoma 8 – 12 cm from anal verge. No other polyp was found.

USG – large right adnexal mass 11 cm in length extending inferiorly and merging with rectal wall.

*Consultant,**Clinical Assistant, Department of Surgery; ***DNB Student; Holy Family Hospital, Bandra, Mumbai.

CT scan abdomen + pelvis (plain + contrast with rectal contrast) – large polypoidal rectal mass with pericolic fat stranding and regional nodes. Malignancy likely.

CEA – 1.16

She was taken up for surgery a week after admission.

A low anterior resection of rectum, with hand sewn anastomosis was performed with dissection of multiple enlarged lymph nodes. Meckels diverticulum was an incidental finding.

Gross examination – 9 x 5 cm, friable, sessile mass

Microscopy – TV adenoma. No evidence of malignancy. Reactive hyperplasia of lymphnodes.

Post of Recovery uneventful.

Discussion

Rectal prolapse represents full thickness protrusion of rectum through anal sphincter mechanism. The current concept of aetiology of colorectal adenocarcinoma is based on multistep genetics sequence of events which lead to the transformation of normal mucosa to adenoma and finally cancer. The incidence of invasive cancer increasing with size as there is a 50% chance of villous adenoma more than 1 cm been a cancer. Adenomas are uncommon in people younger than 30 yrs unless those with a significant family history, while prevalence of sporadic adenoma, increasing after age of 50.

Resection of small rectal polyps can be

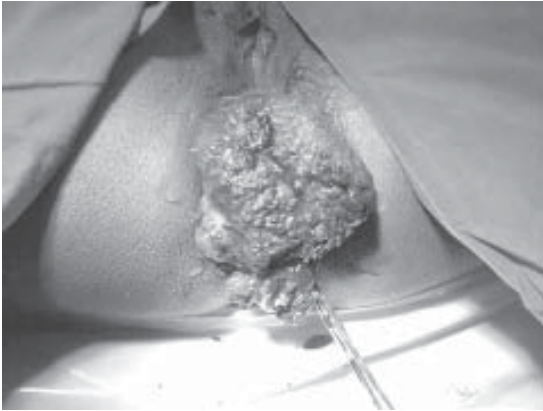


Fig. 1 : Photograph showing prolapsed rectal mass on admission

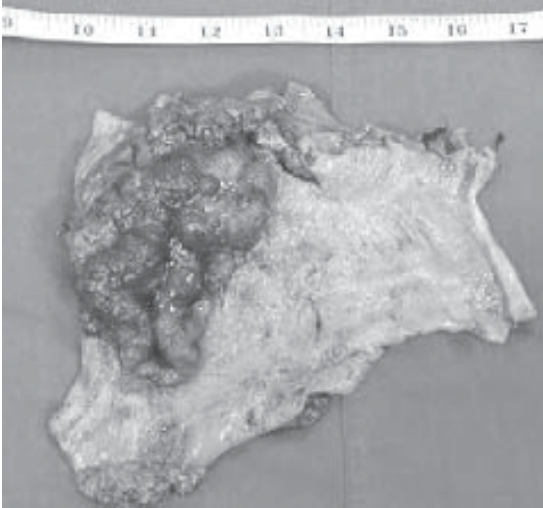


Fig. 2 : Postoperative specimen of Tubulovillous adenoma

dealt with adequately through the endoscope but larger ones are more demanding. Current treatment options include Transanal endoscopic micro surgery (TEMS) which is technically demanding and is limited to a few institutes in UK.

Perineal recto sigmoidostomy or alteimers procedure can be done with the pt in lithotomy position. Low anterior resection of rectum offers the advantage of completely removing the portion of bowel containing the cancer and the lymphatics while the intestinal

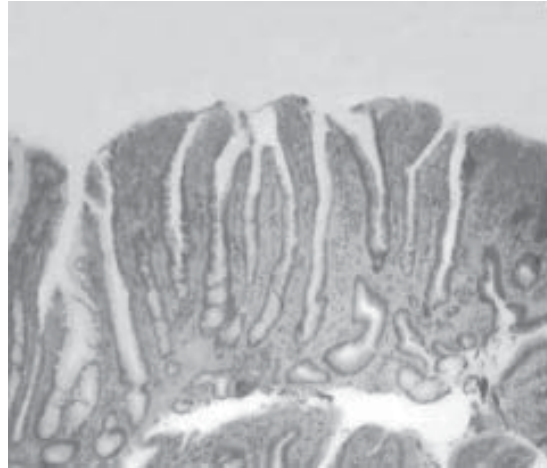


Fig. 3 : Histopathology of the specimen

continuity is established by staplers or hand serum anastomosis.

Rectal tubulovillous adenoma presenting as rectal prolapse in a young pt is rare. As most cases reported in literature are those of pts in their 6th or 7th decade. Rarer still is its association with recurrent cystosarcoma phyllordis of breast.

References

1. Makoto Kaneda, Tamotsu Houta, Makoto Iwasa, Hisao Tamaki (Villous adenoma and rectal prolapse) *Jpn J Gastroenterology Surgery* 1994; 27 : 824-8.
2. Shah PR, Joseph A, Hinduja PN, Kikeru S. Giant villous adenoma presenting as incarcerated rectal prolapse. *IJS* 2005; 67 : 100-101.
3. Disease of colon and rectum (Springer, New York, Volume 26, No. 7).
4. Vogelstein B, Fear ER, Hamilton SR, Kern SE, Presinger AC, Lippert M, Nakamura Y, White R, Smiths. Genetic alterations during colorectal tumor developmrnt
5. *RCSED Journal* vol 146-5/4650009
6. Kissin MW, Wilkns RA. Complete prolapse of massive rectal villous adenoma
7. Bhupinder S Anand, Gordana Verstoves, George Cole. Tubulovillous adenoma of inner canal. *World Journal of Gastroenterology* 2006; 12 (11) : 1780-1.