

Diffused Liver Haemangiomas in An Adult

GD Bakhshi*, Aftab Shaikh**, Ashok D Borisa**, C Alagappan***,
Ashis Patnaik***, BM Subnis****

Abstract

Diffuse haemangiomas of the liver is a rare condition in adults.¹ The aetiology and clinical evolution are not well understood, and the literature shows isolated cases with different behaviours and treatments. We present a case of a 65 years old male with diffuse haemangiomas in both lobes of the liver, causing a bloated sensation in the presence of an abdominal mass. His hepatic and haematological functions were normal. Conventional ultrasound and Computed Tomography (CT) scan revealed diffuse lesions in both hepatic lobes. Histopathology of ultrasound guided biopsy confirmed the diagnosis. As the findings consisted of involvement of both lobes of the liver, radical treatment of a resective type was not possible. Hence conservative management was advised. After one year of follow-up, the patient still complains of an abdominal mass with normal hepatic functions. To the best of our knowledge this is a rare case of diffuse haemangiomas in elderly male.

Introduction

Liver haemangiomas is defined as extensive haemangioma in the liver. Although haemangioma is the most common hepatic tumour, diffuse hepatic haemangiomas is very rare. Most cases of hepatic haemangiomas are seen in infancy, but it is extremely rare in adults.¹ Haemangiomas of the liver is growing in the last decades, because of the abdominal imaging procedures. We discuss the presentation and treatment modalities of these tumours.

Case Report

We present a case of 65 year old male who presented to us with lump in right hypochondrium and epigastrium since 1 year. He had no abdominal complaints besides lump. His bladder and bowel habits were normal and he had no addictions. Clinical examination revealed hepatomegaly. His Ultrasound revealed enlarged liver with multiple hypoechoic

lesions in both lobes of liver suggestive of either metastasis in liver or haemangiomas of liver. His Haematological and liver profile were normal with normal level of hepatic enzymes and albumin/ globulin ratio maintained. His tumour markers viz; Beta human chorionic gonadotropin (β -hCG), Carcinoembryonic antigen (CEA) and Alpha foetoprotein (AFP) were within normal range. CT scan showed large lobulated peripherally enhancing lesion with centripetal filling of contrast and turning isodense on delayed scan. The lesion had replaced most of left lobe and segment 8 and 5 of right lobe. Similar small lesions were seen in segment 6 and 7 of liver (Fig. 1). This was suggestive of diffuse haemangiomas of liver. His coeliac axis angiography revealed soft tissue hypervascular diffuse lesion of liver confirming it to be diffuse haemangiomas. USG guided biopsy confirmed it to be a vascular tumour. In view of diffuse haemangiomas resective treatment was not possible, hence patient was assured about the benign nature of disease and kept under surveillance. Follow up of one year has shown him to be asymptomatic except the lump with normal liver function test.

Discussion

Diffuse hepatic haemangiomas without extrahepatic lesions is extremely rare in

*Assoc. Prof.; **Lecturer; ***Resident; ****Professor of Surgery, Department of General Surgery, Grant Medical College and J.J. Group of Hospitals, Mumbai - 400008

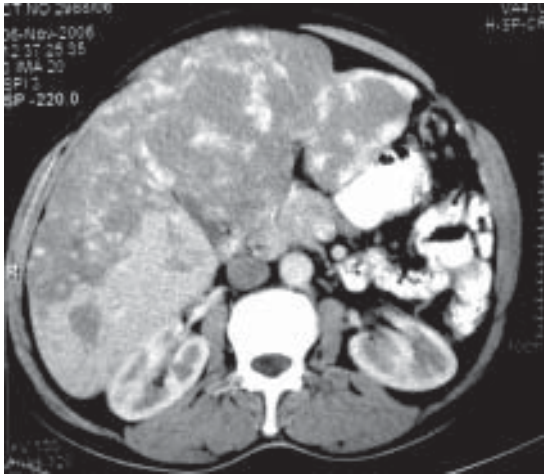


Fig. 1 : CT scan showing diffuse haemangiomas involving both lobes of liver.

adults.¹ Haemangiomas of the liver are often incidental findings on routine abdominal ultrasonography. Majority are single and asymptomatic. Although diffuse hepatic haemangiomas is a rare disease in adults, its diagnosis should be considered in patients with diffuse tumour growth in one or both hepatic lobes and distinguished from malignant tumours. Diffuse hepatic haemangiomas usually presents in infancy as an abdominal mass or as unexplained congestive heart failure.² Haemangiomas acts as an intrahepatic arteriovenous shunting, leading to high cardiac output condition and thus congestive cardiac failure.² In contrast diffuse liver haemangiomas is extremely rare in adults, and only a few patients with isolated liver haemangiomas have been reported in English literature.³

In some patients, the disease is associated with Rendu-Osler-Weber's disease or skeletal haemangiomas or hereditary haemorrhagic telangiectasia.⁴

Rendu-Osler-Weber's disease is a systemic fibrovascular dysplasia with autosomal dominant inheritance.⁴ Epistaxis and cutaneous mucous telangiectasia of the face,

hands and the oral cavity are the most frequent symptoms. Involvement of the gut with haemorrhage and of other organs, including lung, central nervous system and liver have been described.⁴ Our patient did not show any signs of Rendu-Osler-Weber's disease.

The aetiology and natural history of diffuse liver haemangiomas are not well understood. Lehmann et al reported that liver haemangiomas was regarded as an angiogenesis dependent condition with phase of activation and regression.³ Factors that modulate tumour growth are poorly understood. The role of sex hormones and steroid medication during the development of liver cavernous haemangiomas are reported.³ One patient who had received metoclopramide developed diffuse liver haemangiomas and arteriovenous shunting.³ There was no history of steroid or oestrogen intake in our patient.

Small haemangiomas of the liver usually present no symptoms, but giant haemangiomas and diffuse haemangiomas present symptoms of abdominal pain, discomfort and palpable mass and often intrahepatic arteriovenous shunts leading to high cardiac output state and eventually to heart failure.³ Rare complications include rupture, thrombocytopenia and consumptive coagulopathy. Our patient presented with lump and no other symptoms.

The diagnosis of hepatic haemangiomas can be suspected by ultrasonography, CT, Magnetic Resonance Imaging (MRI) and hepatic arteriography, and has to be confirmed histologically. The histological features are characterized by the presence of large vascular channels which are not restricted to the cavernous tumour parts but are also found in the otherwise normal

appearing parenchyma.³ In our case CT scan and biopsy confirmed the diagnosis.

There are several treatment methods for diffuse liver haemangiomas like hepatic artery embolisation or ligation or radiotherapy.⁵ A previous study has shown that a symptomatic giant haemangioma within one lobe should be treated by hepatectomy, but if it involves both lobes, ligation of the hepatic artery with or without radiation should be considered.⁵ Surgery is not generally recommended because of poor delineation of the tumour boundaries and risk of intraoperative haemorrhage. We believe that non-surgical treatments are effective for unresectable cases. Liver transplantation should be considered in patients with congestive heart failure and in whom the other treatment methods will not be applicable.

The prognosis of reported isolated diffuse liver haemangiomas is uncertain because of the rarity of this disease. Lehmann et al described a case of diffuse liver haemangiomas of the left hepatic lobe, who developed progressive tumour growth in

the right lobe after left hepatectomy.³

Our case suggests that diffuse liver haemangiomas can affect patients at any age and it should be considered in patients with multiple tumour growth in one or both lobes. Until more cases of diffuse liver haemangiomas are intensely studied, the natural history and prognosis cannot be established.

References

1. Moon WS, YU HC, Lee JM, Kang MJ. Diffuse hepatic hemangiomas in an adult. *J Korean Med Sci* 2000; 15 : 471-4.
2. Vorse HB, Smith EI, Luckstead EF, Fraser JJ Jr. Hepatic hemangiomas of infancy. *Am J Dis Child* 1983; 137 : 672-3.
3. Lehmann FS, Beglinger C, Schnabel K, Terracciano L. Progressive development of diffuse liver hemangiomas. *J Hepatol* 1999; 30: 951-4.
4. Bernard G, Mion F, Henry L, Plauchu H, Paliard P. Hepatic involvement in hereditary hemorrhagic telangiectasia: clinical, radiological and hemodynamic studies of 11 cases. *Gastroenterology* 1993; 105 : 482-7.
5. Kawarad Y, Mizumoto R. Surgical Treatment of Giant Hemangiomas of the liver. *Am J Surg* 1984; 148 : 287-91.

ARTHROSCOPIC SURGERY FOR OSTEOARTHRITIS OF THE KNEE

This randomized trial showed no benefit of the addition of arthroscopic treatment to optimized physical and medical therapy and provided evidence that arthroscopic surgery is not indicated for the treatment of osteoarthritis of the knee.

N Engl J Med, 2008; 359 : 1097,1169,1195.