

# Ileal Enteroliths Mimicking Bladder Calculi

Ashok D Borisa\*, Girish D Bakhshi\*\*, Mukund B Tayade\*\*\*,  
Satyaheet G Pathrikar\*, Gururaj Deshpande+, Nitin Joshi++

## Abstract

Indigenous small bowel enteroliths is a rare entity, but its presentation mimicking urinary bladder calculi on radiographs was quite amazing. Patient presented with urinary complaints and plain radiographs showing radio-opaque densities in the region of bladder. However further investigation revealed them to be in close proximity to bladder. Diagnosis of enteroliths was confirmed only on exploratory laparotomy. We report a case of enterolithiasis to emphasize the importance of this clinical entity and to highlight its varied presentation.

## Introduction

Calculous diseases in Urinary tract as well as Gastrointestinal tract can be asymptomatic till the advanced stage. In small intestine stasis is the most common factor. Enteroliths have been reported in the bowel affected by Tuberculosis<sup>1</sup> in the form of multiple strictures or in the diverticulae of small intestine mostly in the Meckel's Diverticulum<sup>2</sup> or non-Meckel's diverticulum. Ulcerative colitis, Crohn's disease, carcinoid tumour, post-traumatic or post-surgical strictures have been also associated with enteroliths. Enteroliths resulting from calculi dislodged from the gall bladder containing mainly bile acids have been reported previously. Enteroliths are a result of sub-acute or chronic intestinal obstruction rather than a cause for obstruction. Duodenal and jejunal enteroliths often form in acidic medium and are generally non-radio opaque. The lower part of the small intestine being alkaline is conducive to the precipitation of calcium and hence enteroliths in this location

are radio-opaque. These enteroliths may have a nidus of bacterial or cellular debris or a fruit stone. Sub-acute or chronic intestinal obstruction due to tuberculosis is expected to provide ideal conditions for 'enterolith' formation. But surprisingly its occurrence seems to be very rare.

## Case Report

A 42 year old male was referred to us with complaints of burning micturition and with abdominal radiographs suggestive of radio-opaque densities in the pelvic region. Patient had no history of bowel complaints. In view of his urinary complaints our initial suspicion was bladder calculi. Ultrasonography (USG) revealed multiple renal and hepatic cysts but it could not localise exact site of calculi. Repeated X-rays were showing calculi in same position (Fig. 1). Intravenous pyelography (IVP) showed radio-opaque densities out of the urinary bladder but adjacent to it. It also ruled out bladder diverticulum. To aid our diagnosis we got Computed Tomography (CT) scan of abdomen and pelvis which revealed that the radio-opaque substances were outside the bladder, with a differential of enterolith or loose peritoneal bodies (Fig. 2).

Exploratory laparotomy revealed three round enteroliths in the ileum, which were held by a single distal stricture (Fig. 3). There was no evidence of chronic granulomatous disease in the abdomen, no diverticulum and gall bladder was normal. Enteroliths were removed by enterotomy and a biopsy was taken from the stricture wall. Strictureplasty was done. Post-

---

\*Lecturer; \*\*Associate Professor; \*\*\*Professor and Unit Head; +Resident; ++Senior Resident; Dept of General Surgery, Grant Medical College, Sir J J Group of Hospitals, Mumbai - 400 008.

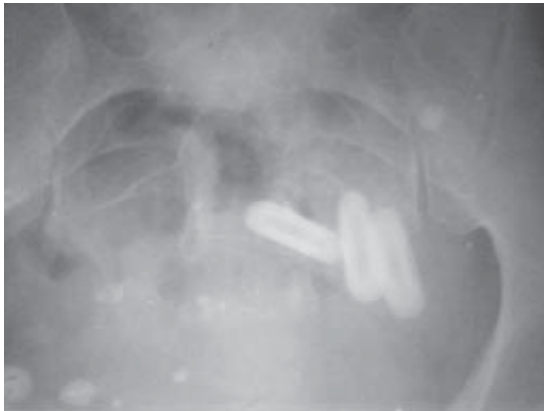

Fig. 1 : X-ray showing Radio opaque densities in Pelvis

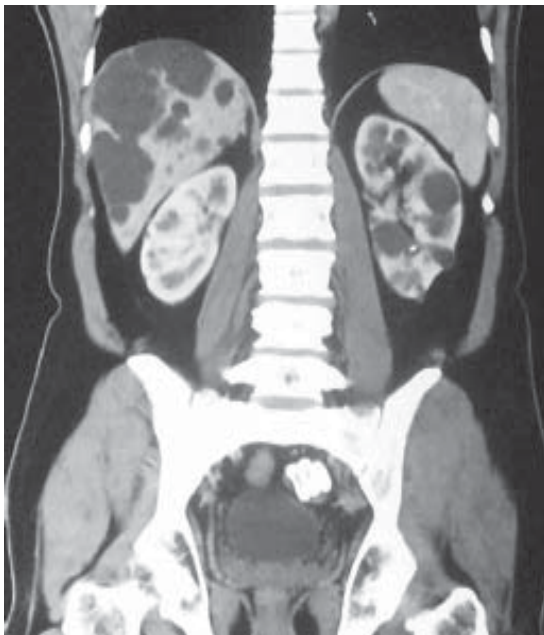

Fig. 2 : CT Scan showing calculi near bladder

operative recovery was uneventful. Histopathology of specimen revealed non-specific stricture with no evidence of tuberculosis or malignancy. Follow up of 1 year has shown patient to be symptom and disease free.

### Discussion

Enterolithiasis is a rarely encountered clinical and radiological entity.<sup>3</sup> Though tuberculosis is a common cause for intestinal strictures in India, the incidence of associated

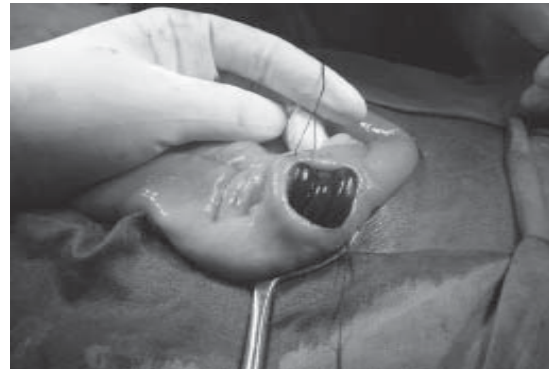


Fig. 3 : Intra-operative photograph showing ileal enteroliths proximal to stricture

enteroliths as reported in the literature is very low. Enteroliths, the endogenous foreign bodies were first described by Pfahler and Stamm in 1915, but enteroliths causing ileus similar to gallstone ileus was first reported in 1921 by Philips. Enteroliths have been reported proximal to a post operative stricture in a patient who had surgery for colon carcinoma.<sup>4</sup> Paige *et al* have published a series of 14 cases with enterolithiasis; 12 patients had stones in the small bowel and two had stones in the colon proximal to strictures, complicating ulcerative colitis.<sup>5</sup> True Enteroliths of any kind are rare. Majority are associated with some mechanical obstructive cause, which allows retention of concretions in the intestines. This can be a post operative stricture of the terminal ileum,<sup>6</sup> or Tuberculous stricture,<sup>7,8</sup> or diverticular disease. The presence of foreign body is favourable for stone formation as they cause stasis and can also act as nucleus around which solid material may be deposited.

CT scan can give a provisional diagnosis, however it may not be possible to differentiate between enteroliths and loose peritoneal bodies in absence of bowel complaints. Hence surgery is mainstay for final diagnosis.

To conclude, enterolithiasis should be a

diagnostic consideration in patients presenting with radio opaque density in pelvis.

#### References

1. Bery K, Chawla S, Gupta SK. Enteroliths and Intestinal Tuberculosis. *Ind J Radiol Imag* 1985; 39 : 225-30.
2. Van EHW, Sybrandy R. Case 19: Enteroliths in a Meckel's diverticulae. *Radiology* 2000; 214 : 524-6.
3. Javors BR, Bryk D. Enterolithiasis: a report of four cases. *Gastrointest- Radiol* 1983; 8 : 359-62.
4. Klinger PJ, Seelig MH, Floch NR, *et al.* Small intestinal Enteroliths—Unusual cause of small intestinal obstruction report of three cases. *Dis Colon Rectum* 1999; 42 : 676-9.
5. Paige ML, Ghahremani GG, Brosnan JJ. Laminated radiopaque enteroliths: diagnostic clues to intestinal pathology. *Am J Gastroenterol* 1987; 82 : 432-7.
6. Lantsberg L, Eyal A, Khodadadi J, Hirsch M. Enterolithiasis. *J Clin Gastroenterol* 1988; 10 : 165-8.
7. Gupta SK, Sharma OP, Agrawal AK, Singh AK, Sasibabu K: -91. Enteroliths in Tuberculosis Strictures of Intestines. *Ind J Gast* 1984; 3 : 89.
8. Prakash A. Intestinal Tuberculosis – 18 years review. *Ind J Surg* 1978; 40 : 56-64.

#### THE COMING OF AGE OF ASTHMA GUIDELINES

Despite universal recommendations that the diagnosis of asthma requires an objective measurement of lung function to show airway variability (i.e., an increased bronchodilator response to a fast-acting  $\beta$  agonist), spirometry is seldom used in primary practice and methacholine challenge remains almost unknown.

Instead, it seems more plausible that the harried general practitioner omits spirometry because the measurement is not readily available, is too costly, has not been explained clearly, or requires more time to arrange and evaluate than is available (or seems available) in a busy office.

**R Andrew McIvor, Kenneth R Chapman, The Lancet, 2008; 372 : 1021-22.**