

# Breast Lump : An Initial Manifestation of Primary Tubercular Mastitis

Bhavik M Patel\*, Sadashiv V Pandit\*\*, Rina D Shah\*\*\*, Sonal R Bangde+

## Abstract

We describe an unusual case of breast lump in a 25 year old female that ultimately turned out to be concealed case of underlying tuberculosis. Indian literature has described seven cases of breast tuberculosis with only one case showing AFB to be present, however we in our case have been able to detect AFB.

## Introduction

Tuberculosis of breast is an extremely rare disease, only 500 cases of primary mammary tuberculous mastitis have been documented; most of which are from past generations.<sup>1</sup> Tuberculosis of breast is often confused with either carcinoma of breast or breast abscess.<sup>2</sup> It usually affects young females and lactating mothers.

## Case Report

A 25 year old female presented to us with a lump in the breast since past 2 months along with a solitary sinus without discharge. There was no history of lump increasing or decreasing in size during menstruation. No past history of pulmonary or extra pulmonary tuberculosis, family history was also negative for the same. On examination we found a solitary mobile lump along with a non-discharging sinus, nipple was normal and no axillary lymph nodes were palpable. Haematological investigations revealed a normal Erythrocyte sedimentation rate and White blood cell counts, fine needle aspiration cytology as well as scrapping from the sinus wall were negative in all previous reports for tuberculosis. In view of the above-mentioned findings, decision to do lumpectomy was taken. A circumareolar incision was taken, on reaching the breast tissue multiple lobulated abscesses

\*Clinical Associate, Department of General Surgery;  
\*\*Consultant General Surgeon; \*\*\*Consultant Pathologist; +Consultant Microbiologist, Godrej Memorial Hospital, Mumbai, India.

Reprinted from : BHJ 2007; 49 (1) : 218-19

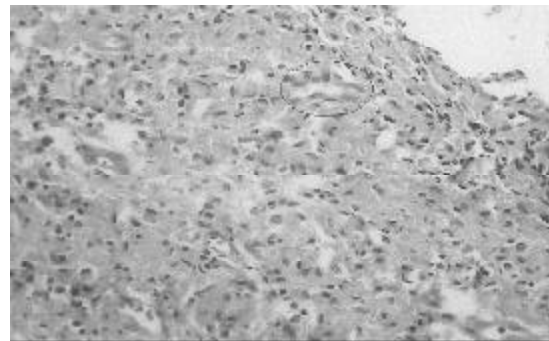


Fig. 1 : Encircled region showing epithelioid cells suggestive of tuberculosis.

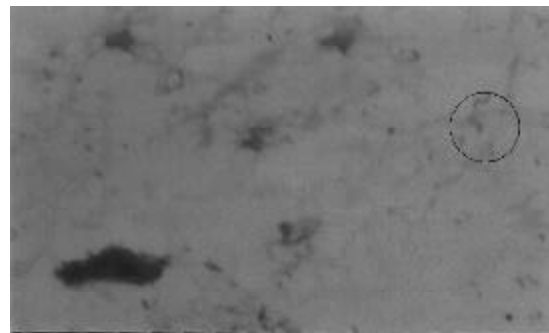


Fig. 2 : Encircled region showing acid fast bacilli suggestive of tuberculosis.

were detected, they were incised, pus was sent for culture and tissue samples for histopathology. The primary incision was closed. Patient was discharged on postoperative day 2. The tissue sample i.e. histopathology report (Fig. 1) was suggestive of tuberculous granuloma. The pus SCAB from breast was suggestive of AFB (Fig. 2). The patient was then

put on 4 drug anti tuberculous drug regimen, is doing fine and there is no evidence of any pulmonary or extra pulmonary tuberculosis.

### **Discussion**

There are three recognized modes of spread of tubercle bacilli to breast, direct, lymphatic and haematogenous<sup>3,4</sup> rarely infected sputum can reach the underlying breast through superficial abrasions of the skin of the breast. In all cases the bacilli infect the ducts and spare the lobules. Dilated ducts of the breast in pregnant and lactating women appear to be especially susceptible to infection.<sup>5</sup> Tuberculosis of the breast has been classified into five different types

1. Acute miliary tuberculosis
2. Nodular tubercular mastitis

3. Disseminated tuberculosis
4. Sclerosing tuberculous mastitis
5. Tuberculosis mastitis obliterans

### **References**

1. Hamit HF, Raygsdale Tit. Mammary tuberculosis (Editorial). *JR Soc Med* 1982; 75 : 76.
2. Schwartz GF. Benign neoplasms and inflammations of the breast. *Clinical Obstetrics Gynaecology* 1982; 25 : 373-85.
3. Algaratham TT, Ong GB. Tuberculosis of breast. *Brit J Surg* 1980; 67 : 125-6.
4. Hale JA, Peters GN, Cheek JH. Tuberculosis of breast rare but still extant; review of literature and report of an additional case. *Amer J Surg* 1985; 150 : 620-4.
5. Mckeown KC, Wilkinson KW. Tuberculosis disease of breast. *British J Surg* 1995; 39 : 420-9.